



**GULF COAST
VETERINARY
SPECIALISTS**

TGCVS Times

ADVANCING COMPASSIONATE VETERINARY CARE

VOLUME 1, ISSUE 3

JULY 2010

SPECIAL POINTS OF INTEREST:

- **CT imaging allows visualization of structures or lesions which may not be detected on routine radiographs**
- **CT imaging of the thorax can be used to detect metastatic disease, assess the extent of thoracic lesions and may aid in radiation therapy planning**
- **Disadvantages with CT imaging include the need for general anesthesia and in some instances—cost of the procedure**

Acupuncture
713.693.1166

Dermatology & Allergy
713.693.1188

Diagnostic Imaging
713.693.1177

Internal Medicine
& Critical Care
713.693.1144

Oncology
713.693.1166

www.gcv.com



Computed Tomography of the Thorax

Figure 1: No definitive pulmonary nodules are seen in this right lateral radiograph. The red line shows the approximate location of the CT slice in figure 2

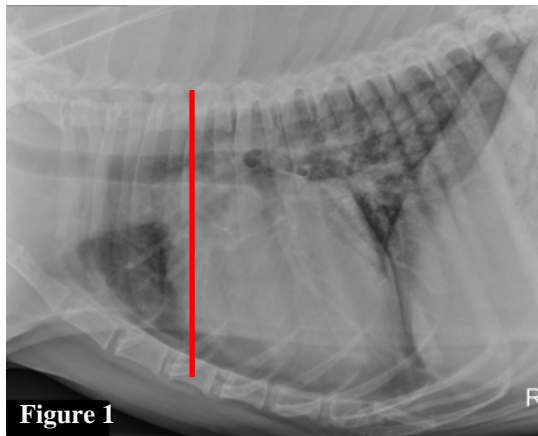


Figure 1

Fig. 2: The pulmonary nodules on the right side of the image could easily be obscured on radiographs due to their proximity along the cranial edge of the heart.

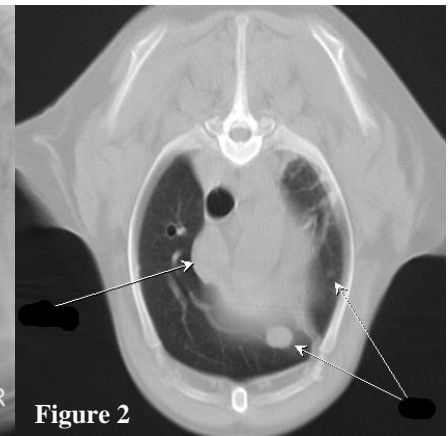


Figure 2

Dear Colleague,

Diagnostic imaging of the thorax is a commonly used tool for evaluating many diseases of the dog and cat. It is extremely important for staging various neoplastic diseases and when forming a treatment plan and prognosis for a patient with cancer. Routinely, survey radiographs are used to evaluate the thorax due to the wide availability, low cost, and relative ease of obtaining the images. Radiographs are the mainstay of thoracic imaging and can provide a wealth of information. However, many times thoracic radiographs are inconclusive and can even be misleading. In these cases, CT evaluation of the thorax provides a much more thorough evaluation.

What are some limitations of routine chest radiographs?

The chief limitation of radiographs is the fact they are a two dimensional representation of a three dimensional object. This means that various structures are superimposed on top of each other in the image, preventing them from being identified as individual structures or even from being identified at all. This limitation originates from the fact that a radiograph is simply a shadow cast by the x-ray tube onto a piece of film, much as a light source casts a shadow of an object on a wall or the floor. Some lesions can be located in a region of the thorax that is difficult to assess fully with radiographs alone. This is due to silhouetting of the lesion with normal structures, such as in the mediastinum. Additionally, when the goal is to identify potentially small or subtle lesions, there is a greater likelihood that they will be obscured by the normal anatomy of the thorax. Finally lesions must be a certain size in order for the radiologist's eyes to detect an abnormality—thus lesions smaller than 2mm have the potential not to be seen.

How does Computed Tomography (CT) work?

CT works by taking a continuous circular x-ray around the patient while sliding the patient on a table through an opening in the center of the machine, called the gantry. When the table is moving through the gantry simultaneously with the circular movement of the x-ray tube in the machine, this is called spiral or helical acquisition. The images are then reconstructed as slices by the computer. CT has the advantage of eliminating all superimposition of structures by being able to look at the thorax much like looking at individual pages of a book. This lack of superimposition as well as a high degree of tissue contrast allows a much greater evaluation of the anatomy and pathology in the region of interest.

What are some indications for CT of the thorax?

The most common indication for CT of the thorax is to evaluate for pulmonary metastatic disease in the staging process for various types of cancer. Many pulmonary nodules are obscured on routine radiographs due to small size or superimposed with ribs, the heart, blood vessels, and various other structures including concurrent pulmonary pathology. Being able to identify metastases has a profound effect on the prognosis and treatment options in many cases. It has been shown that helical CT of the thorax is significantly more sensitive than survey radiographs in the detection of pulmonary nodules. The data in one study of eighteen dogs reflected that approximately 90% of pulmonary nodules detected on CT evaluation were not seen on radiographs (Nemanic S, London CA, and Wisner ER. Comparison of Thoracic Radiographs and Single Breath-Hold Helical CT for Detection of Pulmonary Nodules in Dogs with Metastatic Neoplasia. J Vet Intern Med 2006;20:508–515)

CT can also be used to evaluate the full extent of a lesion. This can be useful in the mediastinum, for pleural based masses, rib lesions, or for a single pulmonary mass to evaluate for potential surgical excision or radiation therapy planning.

Are there disadvantages to CT of the thorax?

The main disadvantage of CT imaging is the need for general anesthesia. Proper patient positioning is vital in obtaining a quality diagnostic study and minimizing artifact. The patient must be perfectly still during the acquisition of images which can take up to about 30 seconds whereas radiographic images are acquired in fractions of a second. Some patients unfortunately who would benefit from CT of the thorax are not healthy enough for even brief anesthesia. Additionally, thoracic CT is more expensive than routine radiographs which can be a limiting factor in some cases. However, the additional cost of CT may be justified if the decision to pursue expensive therapy and/or further diagnostics is predicated on accurate characterization of the disease process.

Does Gulf Coast Veterinary Specialists offer CT imaging of the thorax?

We utilize two CT scanners including a GE multi-slice scanner, which decreases the scan time by obtaining 4 slices simultaneously, resulting in decreased anesthesia time for the patient. CT scans can be done Monday-Friday and are scheduled procedures.

How do I refer a patient for CT scan of the thorax or other area of interest?

If your patient requires advanced imaging and other diagnostics/treatment—you can contact our Medicine Team (713)-693-1114 or Oncology Team (713-693-1166). If you would like to refer your patient solely for a radiology consultation, please contact our Radiology team(713)-693-1177 to discuss an appointment time and coordinate the transfer of any important radiographs and labwork.

www.gcvsv.com

Celebrating 20 years of Compassionate Veterinary Care



1111 West Loop South
Suite 120
Houston, TX 77027

GULF COAST
VETERINARY
SPECIALISTS

To the Doctors of:



Gulf Coast Veterinary Dermatology & Allergy, Gulf Coast Veterinary Diagnostic Imaging, Gulf Coast Veterinary Internal Medicine & Critical Care, and Gulf Coast Veterinary Oncology are now on Facebook